

# ARTICULAR BLEEDING (HEMARTHROSIS) IN HEMOPHILIA

AN ORTHOPEDIST'S POINT OF VIEW

**Second Edition**

**E.C. Rodriguez-Merchan**

Consultant Orthopedic Surgeon  
La Paz University Hospital  
Madrid, Spain

Associate Professor of Orthopedics  
University Autonoma  
Madrid, Spain

Published by the World Federation of Hemophilia (WFH), 2000; revised 2008.

© World Federation of Hemophilia, 2008

The WFH encourages redistribution of its publications for educational purposes by not-for-profit hemophilia organizations. In order to obtain permission to reprint, redistribute, or translate this publication, please contact the Communications Department at the address below.

This publication is accessible from the World Federation of Hemophilia's website at [www.wfh.org](http://www.wfh.org). Additional copies are also available from the WFH at:

World Federation of Hemophilia  
1425 René Lévesque Boulevard West, Suite 1010  
Montréal, Québec H3G 1T7  
CANADA  
Tel. : (514) 875-7944  
Fax : (514) 875-8916  
E-mail: [wfh@wfh.org](mailto:wfh@wfh.org)  
Internet: [www.wfh.org](http://www.wfh.org)

The *Treatment of Hemophilia* series is intended to provide general information on the treatment and management of hemophilia. The World Federation of Hemophilia does not engage in the practice of medicine and under no circumstances recommends particular treatment for specific individuals. Dose schedules and other treatment regimes are continually revised and new side effects recognized. WFH makes no representation, express or implied, that drug doses or other treatment recommendations in this publication are correct. For these reasons it is strongly recommended that individuals seek the advice of a medical adviser and/or consult printed instructions provided by the pharmaceutical company before administering any of the drugs referred to in this monograph.

Statements and opinions expressed here do not necessarily represent the opinions, policies, or recommendations of the World Federation of Hemophilia, its Executive Committee, or its staff.

Treatment of Hemophilia Monographs  
Series Editor  
Dr. Sam Schulman

## Table of Contents

Introduction .....	1
Types of Hemarthroses .....	1
Treatment of Hemarthroses .....	1
Acute hemarthroses .....	1
Subacute hemarthroses .....	3
Recurrent hemarthroses .....	3
Conclusion .....	4
References .....	5



---

# Articular Bleeding (Hemarthrosis) in Hemophilia An Orthopedist's Point of View

---

E. C. Rodriguez-Merchan

---

## Introduction

The most typical manifestation of hemophilia is articular bleeding (hemarthrosis). When hemarthroses become frequent and/or intense, the synovium may not be able to reabsorb the blood. To compensate for such reabsorptive deficiency, the synovium will hypertrophy, resulting in what is called chronic hemophilic synovitis [1-3]. Thus, it is very important not only to avoid acute hemarthrosis, but also to manage it as efficiently as possible, in order to avoid the development of synovitis.

Hematological prophylactic treatment from the age of two to the end of skeletal maturity is the best way to avoid articular bleeds, or at least to diminish their intensity. However, one should remember that problems may be caused by the permanent intravenous infusion needed in such circumstances. Most hemophilia centres in developed countries have on-demand treatment, which consists of the administration of the deficient coagulation factor when hemarthrosis occurs.

## Types of Hemarthroses

It is important to differentiate acute bleeding and subacute bleeding. Subacute hemarthrosis is generally associated with previous synovitis or arthropathy, while acute hemarthrosis commonly occurs in a previously healthy joint [4]. Acute bleeding is usually felt by the patient as a burning sensation in the joint. Hemarthrosis develops within a few hours; the joint becomes inflamed, tense, warm, and the skin becomes bright red. The affected joint is held in an antalgic flexion position, with painful and limited mobility.

After administration of the appropriate doses of factor concentrates, pain will rapidly diminish, although inflammation and limitation of articular mobility commonly disappear more slowly. The degree of inflammation and limitation of motion are always related to the amount of blood in the joint.

Subacute hemarthroses commonly occur after two or three articular bleeding episodes and persist despite adequate hematological treatment. Pain can be tolerable and is commonly associated with hypertrophic synovium on palpation and a slight lack of joint mobility. When subacute hemarthroses recur for months and years, they will result in a state of hemophilic arthropathy. This usually occurs in young adults, who complain of persistent pain in the affected joint, not only with movement, but also at rest. They may also have intermittent episodes of acute pain and inflammation related to synovitis or articular bleeding.

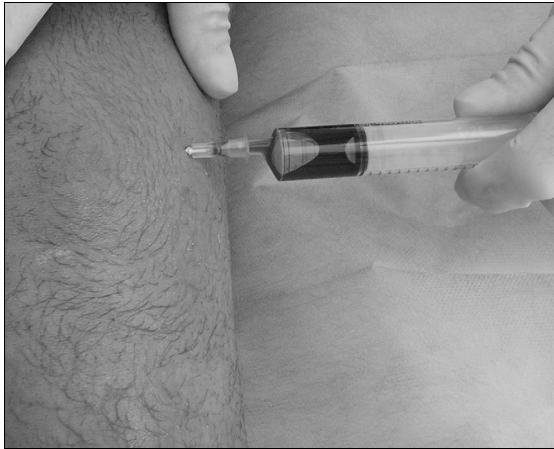
## Treatment of Hemarthroses

### Acute hemarthroses

Optimal treatment of acute hemarthroses involves a combination of factor replacement, joint aspiration, rest (with or without splinting), ice, appropriate analgesia, and supervised rehabilitation once the acute phase has been controlled and the risk of bleeding reduced [5]. The objectives of treatment are to avoid muscular atrophy, maintain an adequate degree of articular mobility, control the recurrence of hemarthroses, and recover joint function if possible.

### *Joint aspiration*

Joint aspiration (arthrocentesis) is not commonly performed, but in cases of severe bleeding it may relieve pain and speed up rehabilitation (Figure 1). There is a great deal of controversy on the role of arthrocentesis in hemophilia. The author's view is that minor bleeding episodes can be treated by other means. However, major bleeds may benefit from joint aspiration, provided it is done within the first 12 hours. Before deciding on joint aspiration, the presence of a circulating inhibitor must be investigated to determine the best treatment for it. In any case, three to four days of joint rest are recommended. When hemarthrosis does not respond to hematological treatment, septic arthritis must be suspected,



**Figure 1.** Hemarthroses must be evacuated by means of arthrocentesis, always under hemostatic control: technique of knee arthrocentesis by the lateral suprapatellar approach.

especially if the patient is immunodepressed; joint aspiration and culture will allow us to reach a diagnosis [6].

If hemarthrosis does not respond to hematological treatment, one must suspect hemophilic synovitis, which can be detected by clinical examination. Ultrasonography and magnetic resonance imaging (MRI) will help confirm the occurrence of synovitis. In such cases, only aggressive treatment of synovitis will control articular bleeding, which is secondary to synovial hypertrophy. Synovitis can be controlled with early prophylactic treatment or by synovectomy (radionuclide synovectomy or surgical synovectomy). Diagnostic imaging is paramount to assess the response to any type treatment.

Heim et al [7] reported an interesting case of a person with hemophilia who had a fixed flexed hip and intractable pain. This clinical picture was suggestive of hemorrhage in that area. Ultrasonography confirmed the diagnosis of acute hip hemarthrosis. Narcotic drugs failed to alleviate the severe pain. Joint aspiration produced dramatic pain relief and early joint rehabilitation. However, Heim et al did not suggest that every coxhemarthrosis should be aspirated.

It should be remembered that raised intra-articular pressure may contribute to femoral

head necrosis in adults, or to Perthes disease in children. It is important to emphasize that while arthrocentesis of the elbow, knee and ankle are quite simple procedures that can be done at the outpatient clinic, both shoulder and hip joint aspirations require sedation and radiographic control by an image intensifier, that is to say, they are surgical procedures done in an operating room, with an anesthetic and by an orthopedic surgeon.

#### *Rest and splinting*

Rest for lower limb bleeding episodes should include bed rest (one day) followed by avoidance of weight-bearing and the use of crutches when ambulating, and elevation when sitting (three to four days). For the knee a compressive bandage is adequate, although in very painful cases the bandage should be supplemented with a long-leg posterior plaster splint. For the ankle, a short-leg posterior plaster splint is recommended. For the upper limb, usually a sling (for the shoulder) or a long-arm posterior plaster splint (for the elbow) will provide sufficient rest, support and protection. Lifting and carrying heavy items should be avoided until the bleeding has resolved (four to five days).

#### *Ice*

Ice therapy relieves pain and reduces the extent of bleeding by promoting vasoconstriction. Ice therapy can be applied to the affected joint in various ways: cold packs, wet towels, crushed ice and Cryo Cuff®. Applications of ice over a 24- to 48-hour period can help control volume of blood and pain. Ice should not be applied directly to the skin, but wrapped in a thick towel, because prolonged application can cause skin damage. The effectiveness of ice as a treatment for acute bleeds lies not only in its physical effects but also in its ease and simplicity of application.

#### *Analgesia*

Depending on the degree of pain, paracetamol or a combination of paracetamol and dextropropoxyphene should be administered. Usually these medications provide adequate relief. Aspirin®-containing products and nonsteroidal anti-inflammatory drugs must be avoided.

### Subacute hemarthroses

It is advisable to treat subacute hemarthroses with hematological substitutive therapy and two to three weeks of immobilization by means of a semi-flexible splint. Some studies recommend six to eight weeks of prophylaxis with physiotherapy. It is recommended to administer enough of the deficient factor, three times a week, to obtain 20-30% of the normal level. After each transfusion, the patient should complete an exercise program focusing on active joint mobility, under the surveillance of an expert physiotherapist. If such mobility exercises are painful, only isometric exercises should be done.

When a flexion contracture does appear, it should be treated early and aggressively by conservative means to avoid its becoming irreversible. Conservative measures include Oxford's inverted dynamic splints, extension-desubluxation hinged casts, dynamic splints, and traction followed by a polypropylene orthosis. Oxford's technique was specially designed for the knee joint and requires admitting the patient to hospital. The lower limb is put in a balanced traction on a semicircular Thomas splint which has a knee flexion Pearson's device. Then soft traction is put on the calf with the heel free; a posterior force is applied on the thigh by means of a cushioned spring located on the distal part of the thigh, which is connected by means of a string to a 3 kg weight. Such a posterior force counteracts the anterior force produced by the springs located on the posterior part of the calf. Both the longitudinal traction and the thigh weight are progressively increased. When the knee becomes fully extended, or if the technique does not work after one week of treatment, the patient is mobilized with a Böhler cast which is open in its anterior part. According to the Oxford authors, hematological therapy is not required [8].

The hinged extension-desubluxation cast can be made of plaster of Paris or of a thermoplastic material; it should be open in its anterior part. The hinge is adjusted once or twice a day to correct the deformity. When the contracture is less than 20°, the cast can be removed and replaced with a plaster splint. Hematological

substitutive therapy is necessary during the procedure. The dynamic splint is adjustable and allows a low intensity but long duration force through the knee joint. A gain of 5° to 10° of knee extension can be expected in six to nine months with this procedure. However, many patients may have hemarthrosis during the follow-up. Traction followed by orthosis is another alternative.

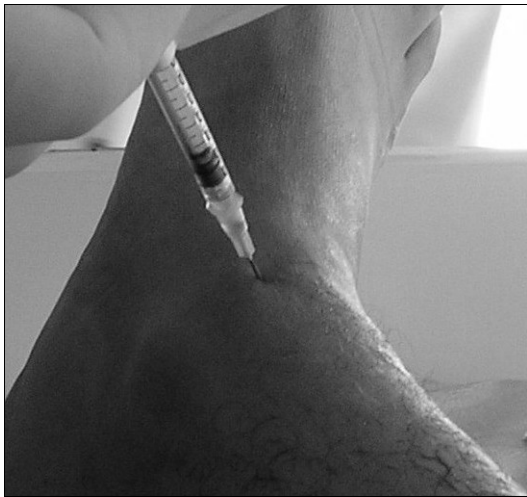Flexion contracture has a different treatment and prognosis, depending on its chronicity and other associated deformities (9). A flexion contracture of few days' duration can be corrected by means of a traction followed by rehabilitation and orthosis. A flexion contracture with a duration ranging from weeks to months may require surgery: hamstring release and/or supracondylar extension osteotomy. A flexion contracture associated with osseous or fibrous ankylosis may also require a patello-femoral osteotomy.

### Recurrent hemarthroses

Radionuclide synovectomy, so-called radioactive synoviorthesis, is an easy to perform and relatively inexpensive procedure (for example, \$150 US for an adult knee). Moreover, it is very efficient in diminishing the frequency and intensity of recurrent hemarthroses related to chronic hypertrophic hemophilic synovitis. It should be performed as soon as possible in order to try to halt the long-term damage that intra-articular blood will cause in the involved joint. Personal experience and the general recommendation among orthopedic surgeons and hematologists is that when three early consecutive synoviortheses (repeated every three months) fail to halt synovitis, a surgical synovectomy (open or by arthroscopy) should be immediately considered.

The main radioactive materials used by the author have been 90-yttrium (90-Y) for the knees and 186-rhenium (186-Rh) for elbows and ankles (Figure 2). Radioactive synoviorthesis is the "gold standard" for the treatment of chronic hemophilic synovitis once hematologic treatment fails. However, given the high cost of radioactive materials and the risk of them being out of date, the

practical reality is that it is necessary to organize groups of patients (e.g. six to eight) to be injected. This means that the first patients of each group could possibly wait from three to six months until the group is complete. In such cases, patients should be in prophylactic hematologic management while waiting. Good coordination between the members of the hemophilia centre, the department of radioactive isotopes, and the enterprises that produce the radioactive material is paramount.



**Figure 2.** Ankle radioactive synoviorthesis with Rhenium-186 for recurrent hemarthroses. The entry point is between the medial malleolus and the tibialis anterior tendon.

Synoviorthesis has a mid- and long-term efficacy of 75-80% [10, 11]. From a clinical point of view, such an efficacy is demonstrated by the decrease (or even disappearance) in the number of hemarthroses. In general terms, it can be said that synoviorthesis has a fibrosing effect on the synovium, transforming a bleeding and richly-vascularized synovium into a sclerotic and poorly-vascularized tissue. It should be emphasized that in 20 to 25% of cases, the first synoviorthesis is not efficient enough and hence should be repeated.

Up to three synoviortheses are recommended, with a three-month interval between them [11]. When repetitive synoviortheses fail, a surgical synovectomy would be indicated.

There is controversy concerning the use of surgical open synovectomy versus arthroscopic synovectomy. The author prefers an open synovectomy, provided that an adequate substitutive hematologic treatment is made and an appropriate post-operative rehabilitation is established.

A review of the literature and the author's 31 years of experience have demonstrated that synoviorthesis is safe. The most serious potential problem in radioactive synoviorthesis is skin burns caused by extravasation of radioactive material from the joint at the time of injection. Echographic-guided injection should be used, if available, to avoid this dangerous complication. Another potential complication is an intense inflammatory reaction that may occur after the procedure. In such cases, rest and nonsteroidal anti-inflammatory drugs commonly solve the problem. In one case, a bilateral ankle 90-Y synoviorthesis eventually caused a bilateral fixed equinus deformity that required a bilateral Achilles tendon lengthening to correct. The potential malignant effects of radioactive synoviorthesis have not been published, despite more than 30 years of experience worldwide.

## Conclusion

Prompt treatment with factor replacement and rest of the affected limb should allow rapid resolution of bleeding episodes with minimal risk of long-term problems. The affected joint should remain at rest for a short period of time (four to five days): bed rest for the hip, a sling for the shoulder, and a compressive bandage and plaster splint for the elbow, knee or ankle. Ice therapy helps to relieve pain and reduce the extent of bleeding. Analgesics (paracetamol) may also be required, depending on the degree of pain. An early and progressive physical therapy is then required to recover the full range of movement and the strength of periarticular muscles. While some authors recommend joint aspiration to remove the blood as an important therapeutic measure, others do not routinely perform this procedure in hemophilia patients. Currently,

arthrocentesis is one of the most controversial issues regarding treatment of hemarthrosis in hemophilia. The author's view is that arthrocentesis should always be performed in major hemarthrosis (voluminous, very tense and painful joint). Minor hemarthrosis commonly responds to hematological treatment and rest. Arthrocentesis of the hip and shoulder should be done under radiographic control in an operating room by an orthopedic surgeon. Aspiration of the elbow, knee and ankle can be performed in the outpatient clinic, not necessarily by an orthopedic surgeon. Joint aspiration should always be done under factor coverage and in aseptic conditions, in order to avoid recurrence or septic arthritis.

Radioactive synoviorthesis is a relatively simple, virtually painless, and inexpensive technique for the treatment of chronic hemophilic synovitis, even in patients with inhibitors. The rate of efficacy of synoviorthesis ranges between 75-80%, and it can be used in patients of any age to diminish the number and intensity of hemarthroses, and to prevent cartilaginous damage. Synoviorthesis may be performed up to three times at three-month intervals. Radioactive synoviorthesis with  $^{90}\text{Y}$  or  $^{186}\text{Re}$  is the optimal procedure to follow, provided it is available.

## References

- Rodriguez-Merchan EC. Pathogenesis, early diagnosis, and prophylaxis for chronic hemophilic synovitis. *Clin Orthop* 1997; 343: 6-11.
- Rodriguez-Merchan EC. Effects of hemophilia on articulations of children and adults. *Clin Orthop* 1996; 328: 7-13.
- Rodriguez-Merchan EC, Magallon M, Galindo E, Lopez-Cabarcos C. Hemophilic synovitis of the knee and elbow. *Clin Orthop* 1997; 343: 47-53.
- Heim M, Rodriguez-Merchan EC, Horoszowski H. Current trends in hemophilia and other coagulation disorders. Orthopaedic complications and management. *Intl J Pediatr Hematol Oncol* 1994; 1: 545-51.
- Ribbans WJ, Giangrande P, Beeton K. Conservative treatment of hemarthrosis for prevention of hemophilic synovitis. *Clin Orthop* 1997; 343: 12-8.
- Rodriguez-Merchan EC, Magallon M, Manso F, Martin-Villar J. Septic arthritis in HIV positive haemophiliacs. Four cases and a literature review. *Int Orthop* 1992; 16: 302-6.
- Heim M, Varon D, Strauss S, Martinowitz U. The management of a person with haemophilia who has a fixed flexed hip and intractable pain. *Haemophilia* 1998; 4: 842-4.
- Stein H, Dickson RA. Reversed dynamic slings for knee flexion contractures in the haemophiliac. *J Bone Joint Surg Br* 1975; 57-B: 282-3.
- Rodriguez-Merchan EC. Management of orthopaedic complications of haemophilia. *J Bone Joint Surg(Br)* 1998; 80-B: 191-6.
- Rodriguez-Merchan EC. Methods to treat chronic haemophilic synovitis. *Haemophilia* 2001; 7: 1-5.
- Rodriguez-Merchan EC. Radionuclide synovectomy (radio synoviorthesis) in hemophilia: a very efficient and single procedure. *Sem Thromb Hemost* 2003; 29: 97-100.





1425 René Lévesque Blvd. W., Suite 1010 Montréal, Québec H3G 1T7 CANADA  
Tel.: +1 (514) 875-7944 Fax: +1 (514) 875-8916  
[www.wfh.org](http://www.wfh.org)